




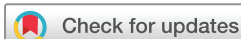# BMJ Open Volume sweep imaging lung teleultrasound for detection of COVID-19 in Peru: a multicentre pilot study

Thomas J Marini <sup>1</sup>, Katherine Kaproth-Joslin,<sup>1</sup> Robert Ambrosini,<sup>1</sup> Timothy M Baran,<sup>1</sup> Ann M Dozier,<sup>1</sup> Yu T Zhao,<sup>1</sup> Malavika Satheesh,<sup>1</sup> Christian Mahony Reátegui-Rivera <sup>2</sup>, Walter Sifuentes,<sup>2</sup> Gloria Rios-Mayhua,<sup>2</sup> Benjamin Castaneda <sup>3</sup>

**To cite:** Marini TJ, Kaproth-Joslin K, Ambrosini R, *et al.* Volume sweep imaging lung teleultrasound for detection of COVID-19 in Peru: a multicentre pilot study. *BMJ Open* 2022;**12**:e061332. doi:10.1136/bmjopen-2022-061332

► Prepublication history and additional supplemental material for this paper are available online. To view these files, please visit the journal online (<http://dx.doi.org/10.1136/bmjopen-2022-061332>).

Received 26 January 2022  
Accepted 03 August 2022



© Author(s) (or their employer(s)) 2022. Re-use permitted under CC BY-NC. No commercial re-use. See rights and permissions. Published by BMJ.

<sup>1</sup>University of Rochester Medical Center, Rochester, New York, USA

<sup>2</sup>Medical Innovation and Technology, San Miguel, Peru

<sup>3</sup>PUCP, Lima, Peru

## Correspondence to

Dr Thomas J Marini;  
rochesterradiology2021@gmail.com

## ABSTRACT

**Objectives** Pulmonary disease is a significant cause of morbidity and mortality in adults and children, but most of the world lacks diagnostic imaging for its assessment. Lung ultrasound is a portable, low-cost, and highly accurate imaging modality for assessment of pulmonary pathology including pneumonia, but its deployment is limited secondary to a lack of trained sonographers. In this study, we piloted a low-cost lung teleultrasound system in rural Peru during the COVID-19 pandemic using lung ultrasound volume sweep imaging (VSI) that can be operated by an individual without prior ultrasound training circumventing many obstacles to ultrasound deployment.

**Design** Pilot study.

**Setting** Study activities took place in five health centres in rural Peru.

**Participants** There were 213 participants presenting to rural health clinics.

**Interventions** Individuals without prior ultrasound experience in rural Peru underwent brief training on how to use the teleultrasound system and perform lung ultrasound VSI. Subsequently, patients attending clinic were scanned by these previously ultrasound-naïve operators with the teleultrasound system.

### Primary and secondary outcome

**measures** Radiologists examined the ultrasound imaging to assess its diagnostic value and identify any pathology. A random subset of 20% of the scans were analysed for inter-reader reliability.

**Results** Lung VSI teleultrasound examinations underwent detailed analysis by two cardiothoracic attending radiologists. Of the examinations, 202 were rated of diagnostic image quality (94.8%, 95% CI 90.9% to 97.4%). There was 91% agreement between radiologists on lung ultrasound interpretation among a 20% sample of all examinations ( $\kappa=0.76$ , 95% CI 0.53 to 0.98). Radiologists were able to identify sequelae of COVID-19 with the predominant finding being B-lines.

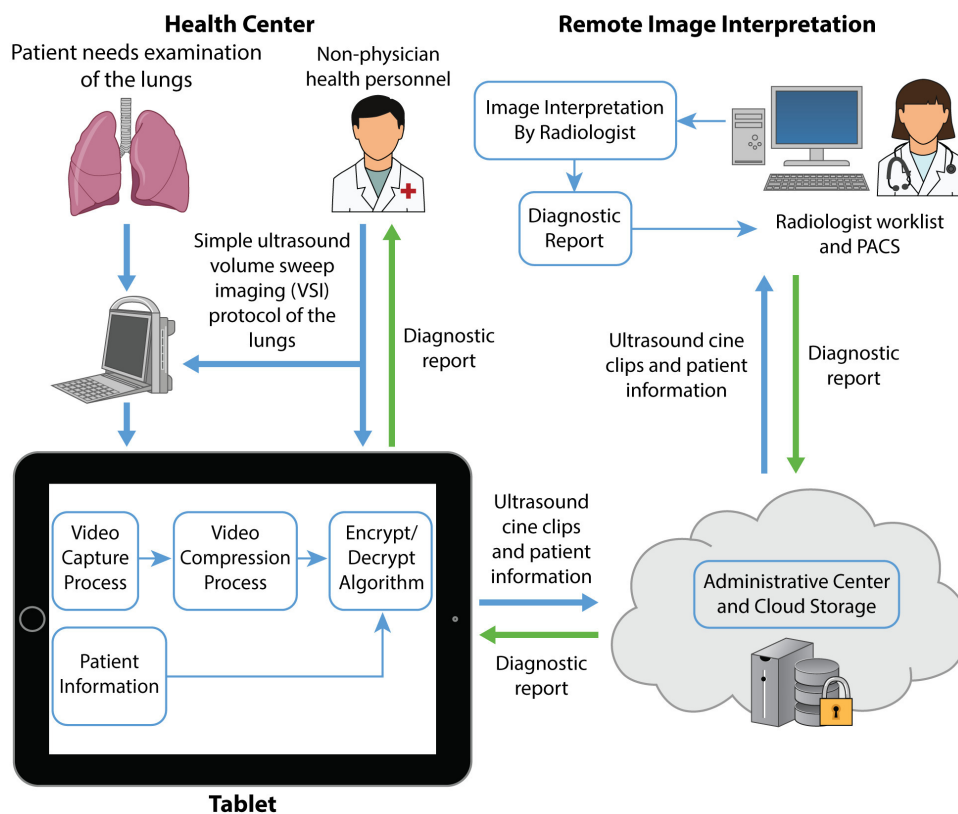
**Conclusion** Lung VSI teleultrasound performed by individuals without prior training allowed diagnostic imaging of the lungs and identification of sequelae of COVID-19 infection. Deployment of lung VSI teleultrasound holds potential as a low-cost means to improve access to imaging around the world.

## STRENGTHS AND LIMITATIONS OF THIS STUDY

- ⇒ Study conducted at multiple health centres in rural Peru during the COVID-19 pandemic.
- ⇒ Lung teleultrasound examinations performed by community members in rural Peru without prior ultrasound experience.
- ⇒ Lung teleultrasound examinations interpreted with standardised reading criteria and two expert cardiothoracic radiologists.
- ⇒ Future study is needed in populations with more diverse respiratory pathology and access to high-quality reference standards.
- ⇒ Future study is needed to assess how teleultrasound can affect health outcomes.

## INTRODUCTION

The leading cause of childhood mortality under 5 years of age is pneumonia.<sup>1</sup> Pulmonary disease, in general, is prevalent worldwide resulting in significant morbidity and mortality, but the majority of the world lacks medical imaging for its assessment.<sup>2-4</sup> Lung ultrasound is a highly accurate tool for diagnosing pulmonary illness including pneumonia, but its deployment is limited by a lack of trained sonographers.<sup>2 3 5 6</sup> Teleultrasound shows great promise in expanding imaging access, but the fundamental problem relating to a lack of specialists persists.<sup>7 8</sup> Volume sweep imaging (VSI) circumvents the problem of a lack of trained sonographers by shifting image acquisition to individuals with minimal medical and ultrasound background through utilisation of standardised sweeps of the ultrasound probe based on external body landmarks which are recorded as video clips for expert remote interpretation.<sup>5 8-11</sup> VSI can be used for a variety of indications including breast, obstetrics, right upper quadrant, and thyroid scanning. Specifically,



**Figure 1** Lung volume sweep imaging (VSI) teleultrasound system. Illustration of the components of the lung teleultrasound system. In this system, individuals without prior ultrasound experience are guided into entering patient clinical history and performing the lung VSI protocol via an application installed on a tablet. The tablet sends the imaging and clinical history to a cloud accessed by a radiologist to produce a diagnostic report. The diagnostic report is sent back to the tablet to be shared with the health centre. Blue arrows represent input of data, and green arrows represent the flow of the diagnostic report. PACS, picture archiving and communication system.

lung ultrasound VSI has been previously tested and shown to be highly effective for pulmonary disease detection including pneumonia.<sup>12</sup> Incorporation of lung ultrasound VSI with telemedicine therefore offers a new way to bring imaging to underserved populations for the evaluation of respiratory diseases.

We hypothesised that lung VSI could be integrated into an asynchronous teleultrasound system to increase access to medical imaging (figure 1). To test this hypothesis, we deployed asynchronous lung VSI teleultrasound to five communities in rural Peru during the COVID-19 pandemic to test the feasibility of lung ultrasound VSI deployment in rural areas. The goal of the study was to evaluate the diagnostic imaging quality of the teleultrasound studies and the feasibility of telemedicine system implementation. This basic verification of proof of concept is necessary prior to resource-intensive controlled clinical trials of VSI teleultrasound compared with standard-of-care ultrasound and larger scale studies of how VSI teleultrasound affects health outcomes.

## METHODS

### Pilot overview

All study procedures were conducted in accordance with the Declaration of Helsinki. Study activities began

in 2020 in the midst of the COVID-19 pandemic. This study was funded and sites of activities chosen by the Peruvian mining company Nexa Resources as a service to the communities they serve without consideration of other factors. These areas were remote regions of Peru including in the Andes mountains (online supplemental figure 1). At each site, the Peruvian company Medical Innovation and Technology trained clinic staff and delivered the equipment necessary to provide lung VSI teleultrasound. Training occurred over the course of a few hours. The study team provided the healthcare staff at the centres a brief didactic explanation of the teleultrasound system. This was followed by hands-on training with the ultrasound probe and the VSI protocol. Additional training on how to use the teleultrasound system was also provided. Typically, mastery of the VSI protocol can be obtained in less than 2 hours with extra training time for reinforcement and practice.<sup>13</sup> Those trained were clinic technicians, clinic nurses, or other clinic staff without prior ultrasound experience. At each centre, a portable Mindray DP-10 (Mindray, China) ultrasound machine was used in this study. Imaging was also obtained with a convex probe using a lung preset with a frequency of 3.5 MHz as this can image a range of patients with acceptable image quality.<sup>5 14</sup> Lung ultrasound imaging can also be

performed with linear and phased array probes, but these were not used in the study.

The primary goal of the study was to evaluate the feasibility of VSI lung ultrasound implementation in rural areas. To this end, patients attending clinic were offered VSI lung teleultrasound examinations for evaluation of concerns of pulmonary pathology including COVID-19. In addition, willing patients were also scanned asymptotically for research purposes to assess the teleultrasound system image quality and function. Only patients who were hemodynamically unstable were excluded from scanning. After written informed consent was obtained, an individual without prior ultrasound experience scanned a patient with the lung VSI protocol using the teleultrasound system. Ultrasound examinations were remotely interpreted by a specialist for assessment of image quality and diagnosis of pulmonary disease. The reports were sent back to the health centres and shared with patients if requested. No changes to the study methods were made during the pilot period. The sample for this study consisted of patients enrolled over the specific time period from November 2020 to June 2021. A specific sample calculation was not performed as we opted to enroll all patients possible during this time period. As this study aimed to demonstrate feasibility, the highest volume of patients available for analysis was ideal. Due to limitations secondary to COVID-19, logistical challenges, and limited study staff, the number of subjects who were asked to participate but declined was unable to be recorded. The study team noted that, in general, very few patients invited to participate in the study declined. All patients enrolled completed a VSI examination, and there were no adverse events.

### Patient and public involvement

This research was undertaken with the purpose of improving access to imaging in rural areas. During our study activities, patients actively provided feedback regarding the lung teleultrasound system. Similarly, staff members at the health centre contributed their feedback and were key partners in advancing the study goals. The outcomes of this study were specifically chosen to assess the efficacy of the teleultrasound system so that its value in these communities could be ascertained. Patients and the public were otherwise not involved in the specific research design of the study. The results of the study will be targeted for dissemination to increase the use of lung teleultrasound in rural and underserved areas.

### Teleultrasound system

The teleultrasound system in this study is shown in [figure 1](#). In this system, patients presenting to the clinic with concern for pulmonary pathology are scanned by an operator using the VSI protocol for lung imaging. Clinical study of lung VSI has shown excellent visualisation of pneumonia, pleural effusion, and pulmonary oedema.<sup>12</sup> This imaging technique is shown in [figure 2](#) and involves sweeps of the ultrasound probe based on external body

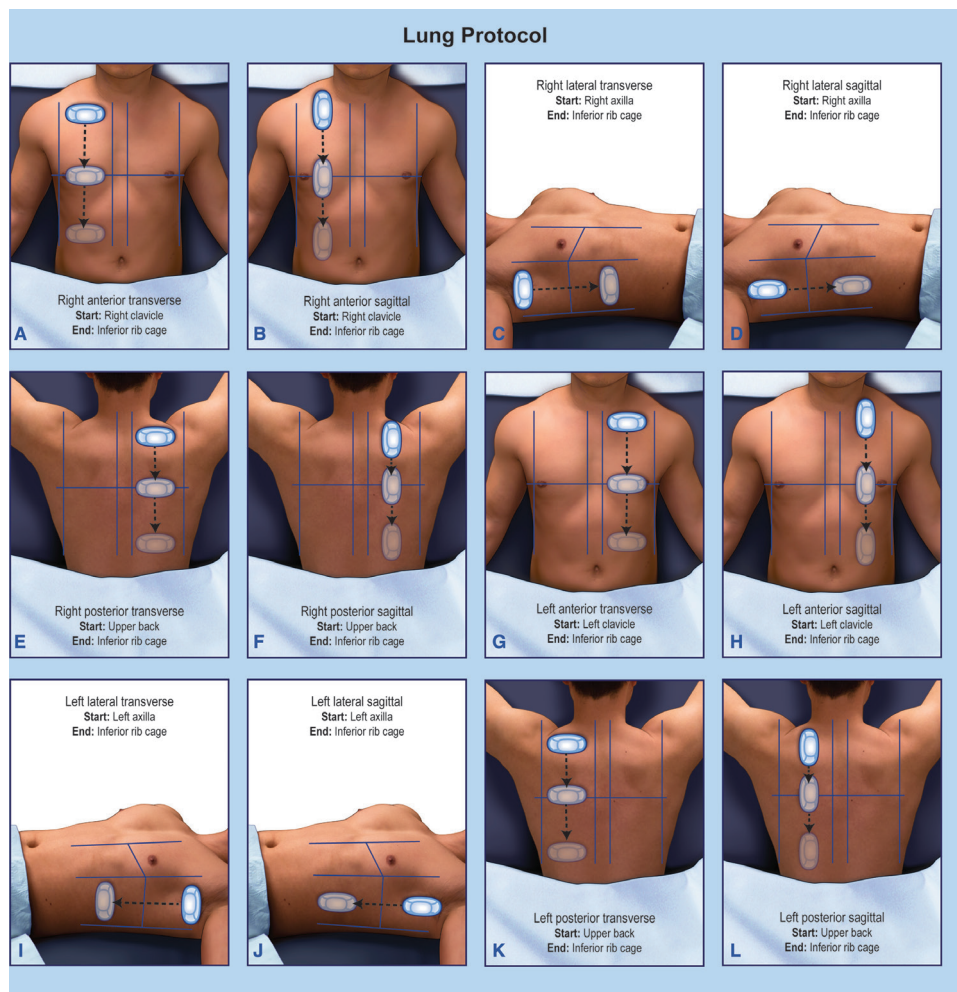
landmarks over the anterior, lateral, and posterior lungs. Acquisitions of each lung field are obtained in the transverse and sagittal orientations for redundancy and improved diagnostic accuracy.<sup>15</sup> Operators are trained to maintain firm probe contact and slowly sweep the probe over the target region. A training video is provided in online supplemental video 1. Individuals, including in rural Peru, have been shown to learn this protocol within 2 hours.<sup>13</sup>

The sweeps of the ultrasound probe are recorded as video clips which are delivered to an expert radiologist for interpretation. In normal standard-of-care ultrasound, a professional sonographer typically obtains imaging of the patient and adjusts the probe positioning and imaging settings to optimise imaging. These images and/or cine clips acquired by the professional sonographer are labelled and sent to the radiologist for interpretation who subsequently produces a report. In contradistinction, the operator in VSI is only sending a video clip with a blinded sweep of the probe over the target region. There is no adjustment of the ultrasound settings or tailored examination to the area of interest. In fact, operators are encouraged to perform the ultrasound sweeps without looking at the ultrasound screen. Instead, they are encouraged to focus on the quality of their sweep by keeping firm probe contact with the skin and holding the probe steady.

With an ultrasound machine operating at 30 frames per second, a 30 s cine clip of a sweep would contain 900 individual frames. The interpreting radiologist can watch the imaging as a video clip or pan through frame by frame similar to a CT scan. The result of performing the lung VSI protocol is a complete volumetric acquisition of each hemithorax. The entire lung is imaged in VSI as opposed to targeted approaches that may only image the area of interest when a specialist is performing the ultrasound. Again, the complete acquisition is necessary since the operator in VSI typically does not have medical or ultrasound background and does not view the screen. Therefore, the interpreting radiologist must be given all of the imaging data available of the lungs for interpretation. This results in a more thorough ultrasound examination than the Bedside Lung Ultrasound in Emergency (BLUE) protocol which has excellent established diagnostic accuracy for respiratory disease with only a fraction of the anatomical coverage.<sup>16</sup> It should be noted that in many cases, only a few key frames in the VSI examination may be necessary to produce a diagnosis.

The sweeps of the ultrasound probes are saved as video clips for remote interpretation by a specialist through the use of a tablet. The tablet has an application installed called MED4US (Medical Innovation and Technology, Peru) which guides the user to input clinic data and acquire each step of the VSI protocol. The tablet compresses and encrypts imaging data and sends it to a cloud for interpretation by a radiologist. The imaging report produced by a radiologist is sent back to the tablet. The teleultrasound system has been shown to operate at low internet speeds around dial-up removing another





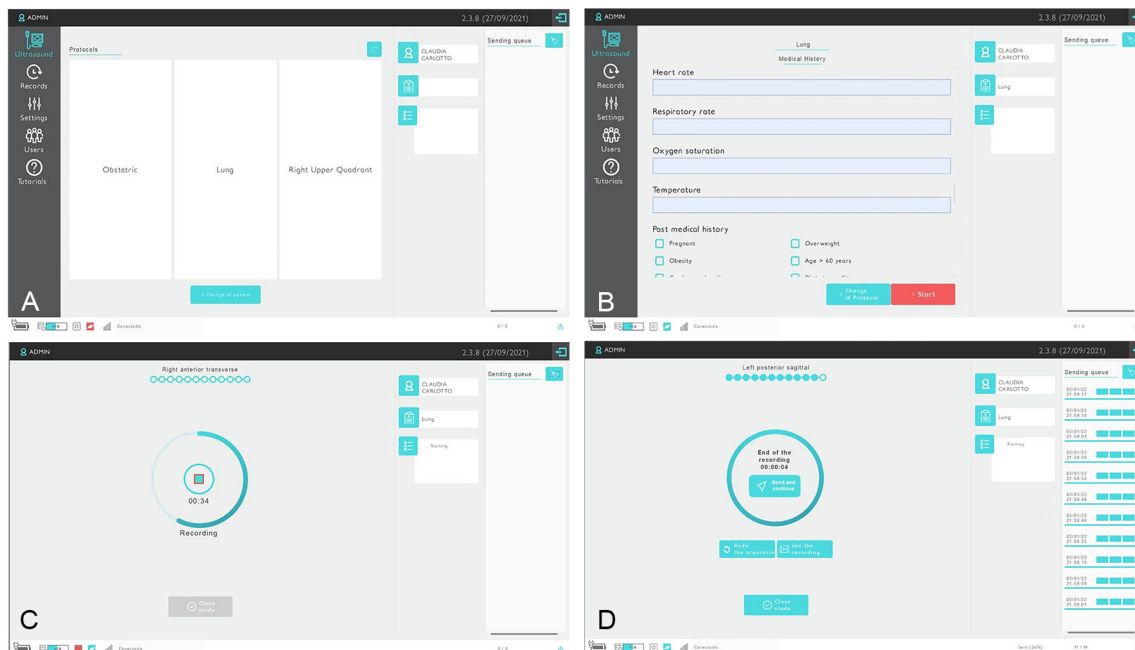
**Figure 2** Lung volume sweep imaging (VSI) protocol. Poster demonstrating each step of the lung VSI protocol performed in this study. Transverse and sagittal orientation scans are acquired in the anterior, lateral, and posterior lung fields. The 12 sweeps compose a full volumetric acquisition of the lungs. A-L represent the order the sweeps were performed in this study with sweep A being the first step and sweep L being the last step.

barrier to imaging access.<sup>8</sup> It can also acquire images locally without internet connection and upload them when internet becomes available. Screenshots of the system are shown in [figure 3](#). This system is an asynchronous telemedicine system, meaning that image acquisitions are acquired in the absence of a specialist and saved for later interpretation. In contrast, synchronous telemedicine requires a high-bandwidth internet connection and the participation of a specialist during image acquisition which may not be available in rural areas. Technical details of the system have been previously published.<sup>8</sup>

### Ultrasound examination analysis

All ultrasound scans were interpreted by an expert radiologist or pulmonologist from Peru. As a special analysis which is the main subject of this paper's content, scans were interpreted by two cardiothoracic attending radiologists in the USA who had access to the clinical history through the telemedicine platform. The examinations were equally split between the radiologists (one reading 106 examinations and the other reading 107 examinations). These radiologists interpreted and rated each

examination sweep by sweep for the presence of A-lines, B-lines, consolidation, pleural effusion, and usability. A final diagnosis was provided after viewing the entire examination along with any free text comments regarding the examination or image quality. The examinations were rated as 'normal', 'borderline', or 'abnormal'. A 'normal' examination had no findings of concern. An 'abnormal' examination showed findings that were deemed unequivocally clinically significant and suspicious for significant pulmonary pathology. 'Borderline' examinations fall in the spectrum between normal and abnormal. These cases often contained a few scattered B-lines of indeterminate clinical significance requiring further monitoring. To assess for inter-reader reliability, 20% of each reader's 'normal', 'borderline', and 'abnormal' examinations were randomly assigned to the other reader. Any examinations rated as 'abnormal' not read by both readers after the random 20% sample were also reinterpreted in a consensus session to ensure agreement on abnormal cases. Overall examination image quality was rated as 'diagnostic', 'limited', or 'non-diagnostic'. The



**Figure 3** Screenshots from the teleultrasound system. (A) Screenshot of the protocol select screen on the tablet. (B) Screenshot of the initial screen to enter patient clinical information after selecting the lung protocol. (C) Screenshot of the recording screen while obtaining a volume sweep imaging (VSI) cine clip. (D) Screenshot showing the recording screen once several VSI clips have been obtained.

radiologists also assessed sweep speed, inclusion of the diaphragm, and probe contact in similar schemes. The turnaround time for reports generated in Peru was also recorded. The reports of the Peruvian radiologists were otherwise not analysed in this study.

Categorical variables are summarised throughout by proportions with 95% CIs, while continuous variables are summarised as mean and SD. Inter-reader agreement on ‘normal’, ‘abnormal’, or ‘borderline’ examination for a subsample was quantified using Cohen’s kappa. All statistical analyses were performed in MATLAB (R2019b, The MathWorks, Natick, Massachusetts).

## RESULTS

Individuals without prior ultrasound experience scanned 213 patients for analysis. Demographics of the patient population are shown in online supplemental table 1. Of these patients, 69% (62.3%–75.2%, n=147/213) were female and 31% (24.8%–37.7%, n=66/213) were male. The average age of the patients was  $42.8 \pm 18.2$  years (range: 0–92 years). Report turnaround time for the Peruvian radiologist was  $18.8 \pm 29.3$  hours (range: 2–279 hours). The 279-hour examination represented a lost examination in the system that was subsequently recovered with staff intervention. Among those scanned, 56.8% (49.9%–63.6%, n=121/213) were asymptomatic and 43.2% (36.4%–50.1%, n=92/213) were reported to have at least one symptom. Presenting symptoms reported included cough (23.9% (18.4%–30.3%, n=51/213)) and feeling generally ill (27.2% (21.4%–33.7%, n=58/213)). Many symptomatic patients scanned had a reported

confirmed case of COVID-19 (30.5% (24.4%–37.2%, n=65/213)) or demonstrated clinical history suspicious for COVID-19 infection. Vitals were often within normal limits among heart rate ( $72.1 \pm 9.31$  beats/min (51–114)), oxygen saturation ( $94.2\% \pm 3.52\%$  (74–99)), and temperature ( $36.5^\circ\text{C} \pm 0.546^\circ\text{C}$  (35–39)). Respiratory rate ( $22.6 \pm 7$  breaths/min (16–40)) was slightly elevated on average.

Of the 213 examinations, 202 were of diagnostic quality (94.8% (90.9%–97.4%)), and there was only a single non-diagnostic examination secondary to a system error. Ten examinations were rated of limited imaging quality (4.69% (2.27%–8.46%)) and thought to be related to body habitus. In perspective, the 213 examinations represented 2556 sweeps of the ultrasound probe. There were 18 sweeps with technical errors from the system, representing 0.7% of all total sweeps. Only one examination had technical errors making it non-diagnostic. In the rest of the cases, the redundant sweeps allowed adequate diagnostic assessment. The most common technical error related to the screen recording of a screensaver instead of the ultrasound imaging. Subsequently, the ultrasound settings were changed to remove the appearance of a screensaver. Results of examinations per sweep are shown in table 1. The average total combined time of ultrasound cine clips was 472 s per examination with a SD of 122 s. All examinations were rated as containing overall adequate sweep speed, inclusion of the diaphragm, and adequate probe contact.

Evaluation of the VSI lung ultrasound examinations by expert radiologists showed the vast majority of sweeps as diagnostically useful (figure 4). Online supplemental

**Table 1** Lung VSI results by sweep

Sweep	1	2	3	4	5	6	7	8	9	10	11	12
A-lines?	99.5% (97.4% to 100%, n=212/213)	100% (98.3% to 100%, n=213/213)	99.5% (97.4% to 100%, n=212/213)	99.5% (97.4% to 100%, n=211/213)	99.5% (96.6% to 100%, n=212/213)	99.1% (96.6% to 99.9%, n=211/213)	99.5% (97.4% to 100%, n=212/213)	99.5% (97.4% to 100%, n=212/213)	99.5% (97.4% to 100%, n=212/213)	99.5% (97.4% to 100%, n=212/213)	98.6% (95.9% to 99.7%, n=210/213)	99.1% (96.6% to 99.9%, n=211/213)
B-lines?	8.92% (5.46% to 13.6%, n=19/213)	9.39% (5.83% to 14.1%, n=20/213)	7.51% (4.35% to 11.9%, n=16/213)	7.51% (4.35% to 11.9%, n=16/213)	6.1% (3.29% to 10.2%, n=13/213)	7.04% (3.99% to 11.3%, n=15/213)	3.76% (1.64% to 7.27%, n=8/213)	4.69% (2.27% to 8.46%, n=10/213)	7.04% (3.99% to 11.3%, n=15/213)	6.1% (3.29% to 10.2%, n=13/213)	8.45% (5.09% to 13%, n=18/213)	9.39% (5.83% to 14.1%, n=20/213)
Diaphragm reached?	99.5% (97.4% to 100%, n=212/213)	100% (98.3% to 100%, n=213/213)	100% (98.3% to 100%, n=213/213)	99.5% (97.4% to 100%, n=212/213)	100% (98.3% to 100%, n=213/213)	99.5% (97.4% to 100%, n=212/213)	99.5% (97.4% to 100%, n=212/213)	99.5% (97.4% to 100%, n=212/213)	99.5% (97.4% to 100%, n=212/213)	99.5% (97.4% to 100%, n=212/213)	99.1% (96.6% to 99.9%, n=211/213)	99.5% (97.4% to 100%, n=212/213)
Technically adequate?	99.5% (97.4% to 100%, n=212/213)	100% (98.3% to 100%, n=213/213)	99.5% (97.4% to 100%, n=212/213)	99.1% (96.6% to 99.9%, n=211/213)	99.5% (97.4% to 100%, n=212/213)	98.6% (95.9% to 99.7%, n=210/213)	99.5% (97.4% to 100%, n=212/213)	99.5% (97.4% to 100%, n=212/213)	99.5% (97.4% to 100%, n=212/213)	99.5% (97.4% to 100%, n=212/213)	98.6% (95.9% to 99.7%, n=210/213)	98.6% (95.9% to 99.7%, n=210/213)
Sweep duration (s)	48.9±16.4	44±13.9	33.6±11.3	31.1±10.4	44.9±12.5	40.4±12.2	44.7±12.9	40.6±12.2	31.8±10.5	30.4±9.85	42.2±12.3	39.4±11.2

Categorical results are presented as proportion (95% CI) and continuous results are presented as mean±SD.

VSI, volume sweep imaging.

videos 2 and 3 show example VSI cine clips. As the majority of patients scanned were asymptomatic, most examinations returned with normal results (n=168). Of all examinations, n=15 were abnormal and n=29 were borderline. Abnormal examinations were thought to be related to COVID-19 infection. The predominant finding on these examinations was B-lines which is consistent with the documented literature on the use of lung ultrasound in COVID-19 infection.<sup>5 17</sup> In no case of suspected or confirmed COVID-19 was there a pleural effusion, findings also consistent with the literature.<sup>18</sup> Borderline imaging frequently demonstrated few scattered or isolated B-lines which can also be seen in mild COVID-19 infection or atelectasis but were of questionable clinical significance.

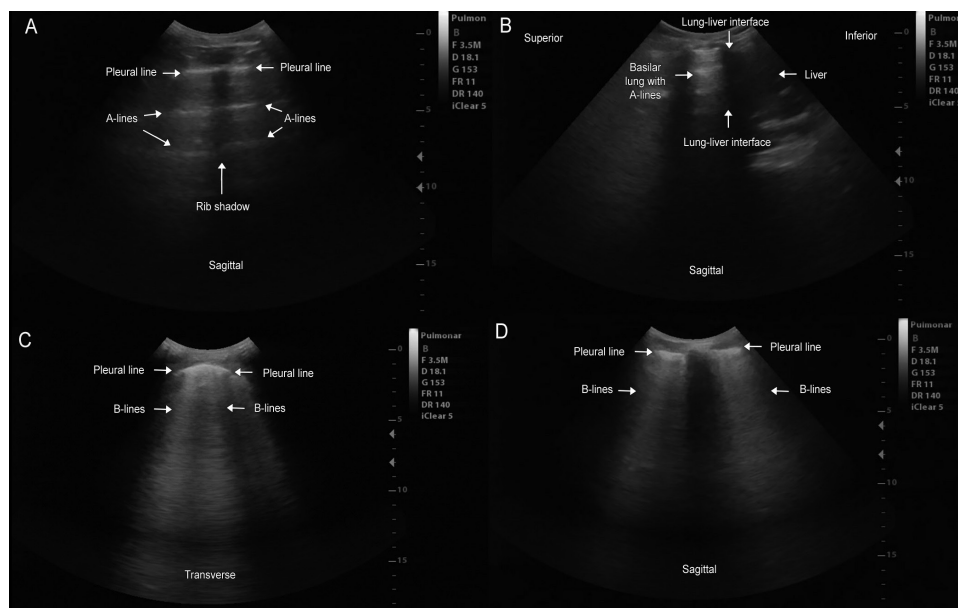
There was 90.7% overall agreement between radiologists on the random 20% sample of lung ultrasound examinations (Cohen's  $\kappa=0.76$ , 95% CI 0.53 to 0.98,  $p<0.0001$ ). This sample represented n=43 cases of which there were four disagreements. All of the disagreements were related to the use of the borderline category. In two of these cases, one reader called the examination normal, and the other called the examination borderline. The other two cases related to one reader calling the examination abnormal and the other calling the examination borderline. Differences in interpretation were thought to represent subjective disagreements in cases which straddled the spectrum between normal and abnormal. In no case did readers offer opposite conflicting interpretations of normal and abnormal supporting this view. Of the 12 abnormal examinations not included in the randomised 20% sample, both readers found the other reader's interpretation reasonable on consensus analysis.

## DISCUSSION

In this study, VSI lung teleultrasound was successfully deployed to rural communities in Peru during the COVID-19 pandemic. Individuals without prior ultrasound training obtained diagnostic images of the lungs after only a few hours of training. Despite multiple sites studied and previously ultrasound-naïve operators, image quality was consistently reported as diagnostic. Furthermore, the deployment of this system (including turnaround time averaging within 1 day) and the generation of near universal diagnostic imaging occurred in the background of a complicated global pandemic posing numerous logistical challenges demonstrating the system's ease of use. For minimal cost, this system could be deployed to increase access to imaging throughout the world. Considering the substantial morbidity and mortality of pulmonary disease and the potential of lung ultrasound VSI to assist in the diagnosis and management of pulmonary disease, deployment of VSI lung teleultrasound could potentially have a significant benefit to the health of the global community.

The study was conducted during the COVID-19 pandemic as an opportunity to study pulmonary disease





**Figure 4** Example images from lung ultrasound volume sweep imaging (VSI) examinations performed by individuals without prior ultrasound experience. (A) Labelled sagittal orientation still image from a VSI sweep with A-lines signifying aerated normal lung in a 7-year-old asymptomatic patient. (B) Labelled sagittal orientation still image from the same sweep more inferiorly shows the basilar lung. The sweep has been submitted as online supplemental video 2. (C) Labelled transverse orientation still image from a VSI sweep with B-lines in a 77-year-old symptomatic patient with confirmed COVID-19 infection. (D) Labelled sagittal orientation still image from the same patient. The sagittal sweep has been submitted as online supplemental video 3.

and increase access to imaging. Our expert imaging interpreters found abnormal pulmonary findings in patients with known or suspected COVID-19 infection. The predominant abnormal finding in these cases is the presence of B-lines. In the current or future pandemics, lung VSI could be employed to both monitor and diagnose respiratory disease in remote areas. Evidence has already suggested lung ultrasound is an effective test for COVID-19 with superior diagnostic performance relative to chest X-ray.<sup>19–22</sup>

Outside of pandemics, the more general use of lung VSI teleultrasound involves the evaluation of pneumonia, pleural effusion, and pulmonary oedema serving a diagnostic function similar to chest X-ray. As with COVID-19, lung ultrasound is thought to be superior to chest X-ray for evaluation of pneumonia, pleural effusion, and pulmonary oedema.<sup>6 23–27</sup> Patients presenting with asthma or mild viral illness should have minimal abnormal findings allowing triage of patients. Like chest X-ray (and to a lesser extent CT), lung ultrasound interpretation is complicated in some cases by overlapping appearance of atelectasis and infection. In these cases, lung ultrasound has an additional advantage over chest X-ray since it does not expose to radiation and can be repeated at no harm to the patient. In cases of severe pulmonary disease requiring emergent medical attention, VSI lung teleultrasound is expected to provide a definitive diagnosis.

There may be inherent scepticism towards the idea of diagnostic images being acquired without a trained sonographer. Consideration of the theoretical aspects of VSI may dispel some doubts regarding this approach. First, it is important to note that point-of-care lung ultrasound

is a well-established imaging technique that individuals regularly perform with brief training.<sup>28 29</sup> VSI is similar to but distinct from a point-of-care approach as the individual acquiring the images is not looking at the screen but simply performing the necessary standardised probe motions for collection of video clips for remote interpretation. One point-of-care lung ultrasound approach called the BLUE protocol has been shown to have over 90% diagnostic accuracy for pulmonary pathology using a fraction of the anatomical coverage of lung VSI which, in distinction, completely images the anterior, lateral, and posterior lungs.<sup>16</sup> When comparing the two protocols and the established accuracy of the BLUE protocol, it should not be surprising that lung VSI has excellent diagnostic utility despite the imaging being obtained by an ultrasound novice.

Additional public health study will be needed to further elucidate how lung VSI can be incorporated into clinical practice in rural or underserved areas. Appropriate follow-up and management need to be in place in the case of abnormal diagnosis. We speculate that primary benefits of VSI would include earlier diagnosis and decreased costs for patients. In paediatric populations, the use of lung VSI would be preferable to chest X-ray in many cases as it does not expose to ionising radiation. Ancillary benefits to lung ultrasound implementation such as increasing clinic attendance and opportunities for vaccination are also possible. These trials will likely require intensive resource investments and time. The feasibility we have shown in this study with the acceptable imaging quality of the teleultrasound system suggests that it would be worthwhile to proceed with such testing.



However, before a large-scale study of VSI is performed to study outcomes, a formal clinical trial of standard-of-care ultrasound compared with VSI in a rural setting may be considered as an intermediary step.

Limitations of VSI are important to acknowledge. Like other ultrasound examinations, VSI can be limited by patient body habitus especially since the operator is not adjusting settings to compensate for suboptimal image quality. The few examinations of limited image quality in this study were thought to relate to issues of body habitus. In addition, experienced sonographers can tailor an examination to an area of suspected pathology, but the motions in VSI are standardised limiting the examination to the available images obtained by the protocol. Although these are important limitations to note, it is also important to realise the alternative to a VSI examination in many situations is likely no imaging at all. In a previous study, the images obtained by the standardised VSI protocol were sufficient to allow diagnosis in all cases even without tailoring the examination to an abnormal finding.<sup>12</sup> Additionally, even suboptimal imaging still can provide useful clinical information. Furthermore, VSI examinations can be repeated at minimal cost as many times as necessary in cases of suboptimal imaging.

A limitation of this study was the radiologist's interpretation of the VSI study without a reference standard for comparison. To partially address this, we performed a specific analysis assessing inter-reader agreement. Future studies in this setting should ideally try to incorporate a reference standard although this will not always readily be available. Previously, we demonstrated high lung ultrasound VSI agreement to standard-of-care chest X-ray in a USA-based hospital setting.<sup>12</sup> It is expected these results would apply in rural areas, but independent verification will still be important if possible. Also, as this was a time-sensitive pilot study based on convenience sampling, formal sample size calculations were not performed prior to opening the study. There is therefore the possibility that the reported results may not accurately reflect the characteristics of the underlying sample. However, 95% CIs are included throughout in order to reflect the ranges of estimated population values. Ultimately, the main goal of this study was to establish feasibility of the approach. Radiologists overwhelmingly rated the VSI imaging as diagnostic which addressed our study question sufficiently. Additionally, it will be important to test the protocol's performance in rural areas outside of the pulmonary pathology seen secondary to COVID-19. Future studies should also deploy the protocol into areas with high prevalence of pneumonia or other respiratory illness. Consideration can also be made to integrating VSI with artificial intelligence to allow for automatic diagnosis without a sonographer or radiologist.<sup>30–36</sup>

## CONCLUSION

Most of the individuals in the world are thought to lack access to diagnostic imaging. In this study, we piloted the

use of a low-cost lung VSI teleultrasound system that can be operated by an individual without prior ultrasound experience after a few hours of training which could help increase access to imaging in populations with the greatest need. Despite the logistical challenges posed by a complicated global pandemic, the system was still successfully deployed at five sites in rural Peru with turnaround times averaging within 24 hours and 95% examinations of diagnostic imaging quality. Radiologists were also able to identify sequelae of COVID-19 infection with high inter-reader reliability. As lung ultrasound is an established imaging technique with high diagnostic accuracy for respiratory illness, lung VSI teleultrasound could bring a powerful diagnostic tool to millions who would otherwise have limited access to imaging.

**Twitter** Thomas J Marini @thomasmarini11, Ann M Dozier @annpdph and Yu T Zhao @TinaZhao906

**Acknowledgements** We thank Nadezhda Kiriyaq, Sarah Klingenberger, Jane Lichorowic, and Gwen Mack for their invaluable support and assistance in the figures and illustrations. We thank Jannette Cong, Susan Hobbs, Deborah Rubens, Matthew Smith, and Michelle Snyder for their invaluable support and assistance in the study.

**Contributors** TJM was involved in study design, study management, data collection, data analysis, and manuscript writing. KK-J and RA read the VSI scans. TMB was involved in statistical analysis of the results. AMD was involved in manuscript writing. YZ and MS were involved in data analysis and manuscript writing. CMR-R, WS, and GR-M were involved in data collection. BC (guarantor) was involved in study design and manuscript writing.

**Funding** The funding for this study was provided by the mining company Nexa Resources. Medical Innovation and Technology provided the logistical support for data collection. Medical Innovation and Technology's operations in this study were funded by Nexa Resources. Those affiliated with Medical Innovation and Technology previewed the manuscript written by the authors of the University of Rochester but did not suggest any changes.

**Disclaimer** Nexa Resources had no further role in the study design, data collection, or manuscript creation. Nexa Resources did not preview the manuscript prior to submission.

**Map disclaimer** The inclusion of any map (including the depiction of any boundaries therein), or of any geographic or locational reference, does not imply the expression of any opinion whatsoever on the part of BMJ concerning the legal status of any country, territory, jurisdiction or area or of its authorities. Any such expression remains solely that of the relevant source and is not endorsed by BMJ. Maps are provided without any warranty of any kind, either express or implied.

**Competing interests** BC has financial stake in Medical Innovation and Technology. This company seeks to bring ultrasound into rural areas. WS, CMR-R, and GR-M are currently employed by Medical Innovation and Technology. WS is the CEO of the company and also has financial stake outside his employment.

**Patient and public involvement** Patients and/or the public were involved in the design, or conduct, or reporting, or dissemination plans of this research. Refer to the Methods section for further details.

**Patient consent for publication** Not applicable.

**Ethics approval** This study involves human participants and was approved by the ethics committee at the Hospital Cayetano Heredia in Peru (ID number: 090-2020). Participants gave informed consent to participate in the study before taking part.

**Provenance and peer review** Not commissioned; externally peer reviewed.

**Data availability statement** Data are available upon reasonable request.

**Supplemental material** This content has been supplied by the author(s). It has not been vetted by BMJ Publishing Group Limited (BMJ) and may not have been peer-reviewed. Any opinions or recommendations discussed are solely those of the author(s) and are not endorsed by BMJ. BMJ disclaims all liability and responsibility arising from any reliance placed on the content. Where the content includes any translated material, BMJ does not warrant the accuracy and reliability



of the translations (including but not limited to local regulations, clinical guidelines, terminology, drug names and drug dosages), and is not responsible for any error and/or omissions arising from translation and adaptation or otherwise.

**Open access** This is an open access article distributed in accordance with the Creative Commons Attribution Non Commercial (CC BY-NC 4.0) license, which permits others to distribute, remix, adapt, build upon this work non-commercially, and license their derivative works on different terms, provided the original work is properly cited, appropriate credit is given, any changes made indicated, and the use is non-commercial. See: <http://creativecommons.org/licenses/by-nc/4.0/>.

#### ORCID iDs

Thomas J Marini <http://orcid.org/0000-0002-1529-5097>

Christian Mahony Reátegui-Rivera <http://orcid.org/0000-0002-4030-8777>

Benjamin Castaneda <http://orcid.org/0000-0002-1913-0636>

#### REFERENCES

- UNICEF. One child dies of pneumonia every 39 seconds, agencies warn [Internet], 2019. Available: [https://www.unicef.org/press-releases/one-child-dies-pneumonia-every-39-seconds-agencies-warn?fbclid=IwAR2ips4pMJvXox8fjaHZWAqm\\_kNyA7WfX\\_MjChRrCw0nNTH3DuOVsuVcz1w](https://www.unicef.org/press-releases/one-child-dies-pneumonia-every-39-seconds-agencies-warn?fbclid=IwAR2ips4pMJvXox8fjaHZWAqm_kNyA7WfX_MjChRrCw0nNTH3DuOVsuVcz1w)
- GBD 2016 Lower Respiratory Infections Collaborators. Estimates of the global, regional, and national morbidity, mortality, and aetiologies of lower respiratory infections in 195 countries, 1990–2016: a systematic analysis for the global burden of disease study 2016. *Lancet Infect Dis* 2018;18:1191–210.
- GBD Chronic Respiratory Disease Collaborators. Prevalence and attributable health burden of chronic respiratory diseases, 1990–2017: a systematic analysis for the global burden of disease study 2017. *Lancet Respir Med* 2020;8:585–96.
- Ngoya PS, Muhogora WE, Pitcher RD. Defining the diagnostic divide: an analysis of registered radiological equipment resources in a low-income African country. *Pan Afr Med J* 2016;25:99.
- Marini TJ, Oppenheimer DC, Baran TM, et al. Testing telediagnostic right upper quadrant abdominal ultrasound in Peru: a new horizon in expanding access to imaging in rural and underserved areas. *PLoS One* 2021;16:e0255919.
- Marini TJ, Rubens DJ, Zhao YT, et al. Lung ultrasound: the essentials. *Radiol Cardiothorac Imaging* 2021;3:e200564.
- Britton N, Miller MA, Safadi S, et al. Tele-Ultrasound in resource-limited settings: a systematic review. *Front Public Health* 2019;7:244.
- Marini TJ, Oppenheimer DC, Baran TM, et al. New ultrasound Telediagnostic system for low-resource areas: pilot results from Peru. *J Ultrasound Med* 2021;40:583–95.
- Marini TJ, Weiss SL, Gupta A, et al. Testing telediagnostic thyroid ultrasound in Peru: a new horizon in expanding access to imaging in rural and underserved areas. *J Endocrinol Invest* 2021;44:2699–2708.
- Toscano M, Marini TJ, Drennan K, et al. Testing telediagnostic obstetric ultrasound in Peru: a new horizon in expanding access to prenatal ultrasound. *BMC Pregnancy Childbirth* 2021;21:328.
- Marini TJ, Castaneda B, Iyer R, et al. Breast ultrasound volume sweep imaging: a new horizon in expanding imaging access for breast cancer detection. *J Ultrasound Med* 2022. doi:10.1002/jum.16047. [Epub ahead of print: 08 Jul 2022] (Epub 2022/07/09).
- Marini TJ, Weis JM, Baran TM, et al. Lung ultrasound volume sweep imaging for respiratory illness: a new horizon in expanding imaging access. *BMJ Open Respir Res* 2021;8:e000919.
- Marini TJ, Castaneda B, Baran T, et al. Lung ultrasound volume sweep imaging for pneumonia detection in rural areas: Piloting training in rural Peru. *J Clin Imaging Sci* 2019;9:35.
- Miller A. Practical approach to lung ultrasound. *BJA Educ* 2016;16:39–45.
- Milliner BHA, Tsung JW. Lung consolidation locations for optimal lung ultrasound scanning in diagnosing pediatric pneumonia. *J Ultrasound Med* 2017;36:2325–8.
- Lichtenstein DA. BLUE-protocol and FALLS-protocol: two applications of lung ultrasound in the critically ill. *Chest* 2015;147:1659–70.
- Convissar DL, Gibson LE, Berra L, et al. Application of lung ultrasound during the COVID-19 pandemic: a narrative review. *2020;131:345–50*.
- Malik J, Javed N, Naeem H, et al. COVID-19 associated pneumonia and pleural effusion masquerading as heart failure in rheumatic heart disease. *Eur J Case Rep Intern Med* 2020;7:001842.
- Brenner DS, Liu GY, Omron R, et al. Diagnostic accuracy of lung ultrasound for SARS-CoV-2: a retrospective cohort study. *Ultrasound J* 2021;13:12.
- Di Gioia CC, Artusi N, Xotta G, et al. Lung ultrasound in ruling out COVID-19 pneumonia in the ED: a multicentre prospective sensitivity study. *Emerg Med J* 2022;39:199–205.
- Pare JR, Camelo I, Mayo KC, et al. Point-Of-Care lung ultrasound is more sensitive than chest radiograph for evaluation of COVID-19. *West J Emerg Med* 2020;21:771–8.
- Trauer MM, Matthies A, Mani N, et al. The utility of lung ultrasound in COVID-19: a systematic scoping review. *Ultrasound* 2020;28:208–22.
- Lichtenstein D, Goldstein I, Mourgeon E, et al. Comparative diagnostic performances of auscultation, chest radiography, and lung ultrasonography in acute respiratory distress syndrome. *Anesthesiology* 2004;100:9–15.
- Maw AM, Hassanin A, Ho PM, et al. Diagnostic accuracy of point-of-care lung ultrasonography and chest radiography in adults with symptoms suggestive of acute decompensated heart failure: a systematic review and meta-analysis. *JAMA Netw Open* 2019;2:e190703.
- Pereda MA, Chavez MA, Hooper-Miele CC, et al. Lung ultrasound for the diagnosis of pneumonia in children: a meta-analysis. *Pediatrics* 2015;135:714–22.
- Xia Y, Ying Y, Wang S, et al. Effectiveness of lung ultrasonography for diagnosis of pneumonia in adults: a systematic review and meta-analysis. *J Thorac Dis* 2016;8:2822–31.
- Ye X, Xiao H, Chen B, et al. Accuracy of lung ultrasonography versus chest radiography for the diagnosis of adult community-acquired pneumonia: review of the literature and meta-analysis. *PLoS One* 2015;10:e0130066.
- Gargani L, Volpicelli G. How I do it: lung ultrasound. *Cardiovasc Ultrasound* 2014;12:25.
- See KC, Ong V, Wong SH, et al. Lung ultrasound training: curriculum implementation and learning trajectory among respiratory therapists. *Intensive Care Med* 2016;42:63–71.
- Barrientos R, Roman-Gonzalez A, Barrientos F. Automatic detection of pneumonia analyzing ultrasound digital images. 2016 IEEE 36th central American and Panama convention (CONCAPAN XXXVI), 2016: 9–11.
- Cisneros-Velarde P, Correa M, Mayta H, et al. Automatic pneumonia detection based on ultrasound video analysis. *Annu Int Conf IEEE Eng Med Biol Soc* 2016;2016:4117–20.
- Correa M, Zimic M, Barrientos F, et al. Automatic classification of pediatric pneumonia based on lung ultrasound pattern recognition. *PLoS One* 2018;13:e0206410.
- Eche G, Zenteno O, Castaneda B. Automatic lung ultrasound B-line recognition in pediatric populations for the detection of pneumonia: SPIE, 2018.
- Zenteno O, Castaneda B, Lavarello R. Spectral-based pneumonia detection tool using ultrasound data from pediatric populations. *Annu Int Conf IEEE Eng Med Biol Soc* 2016;2016:4129–32.
- Zenteno O, Diaz K, Lavarello RJ. An explorative childhood pneumonia analysis based on ultrasonic imaging texture features. *Symposium on medical information processing and analysis*, 2015.
- Arroyo J, Marini TJ, Saavedra AC, et al. No sonographer, no radiologist: new system for automatic prenatal detection of fetal biometry, fetal presentation, and placental location. *PLoS One* 2022;17:e0262107.